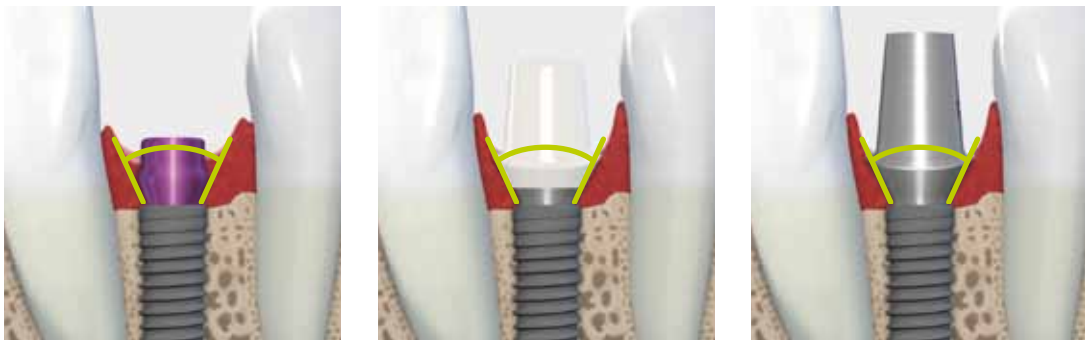

SOFT TISSUE CONDITIONING

WITH THE STRAUMANN® BONE LEVEL IMPLANT SYSTEM



Consistent Emergence Profiles™ concept



The ITI (International Team for Implantology) is academic partner of Institut Straumann in the areas of research and education.

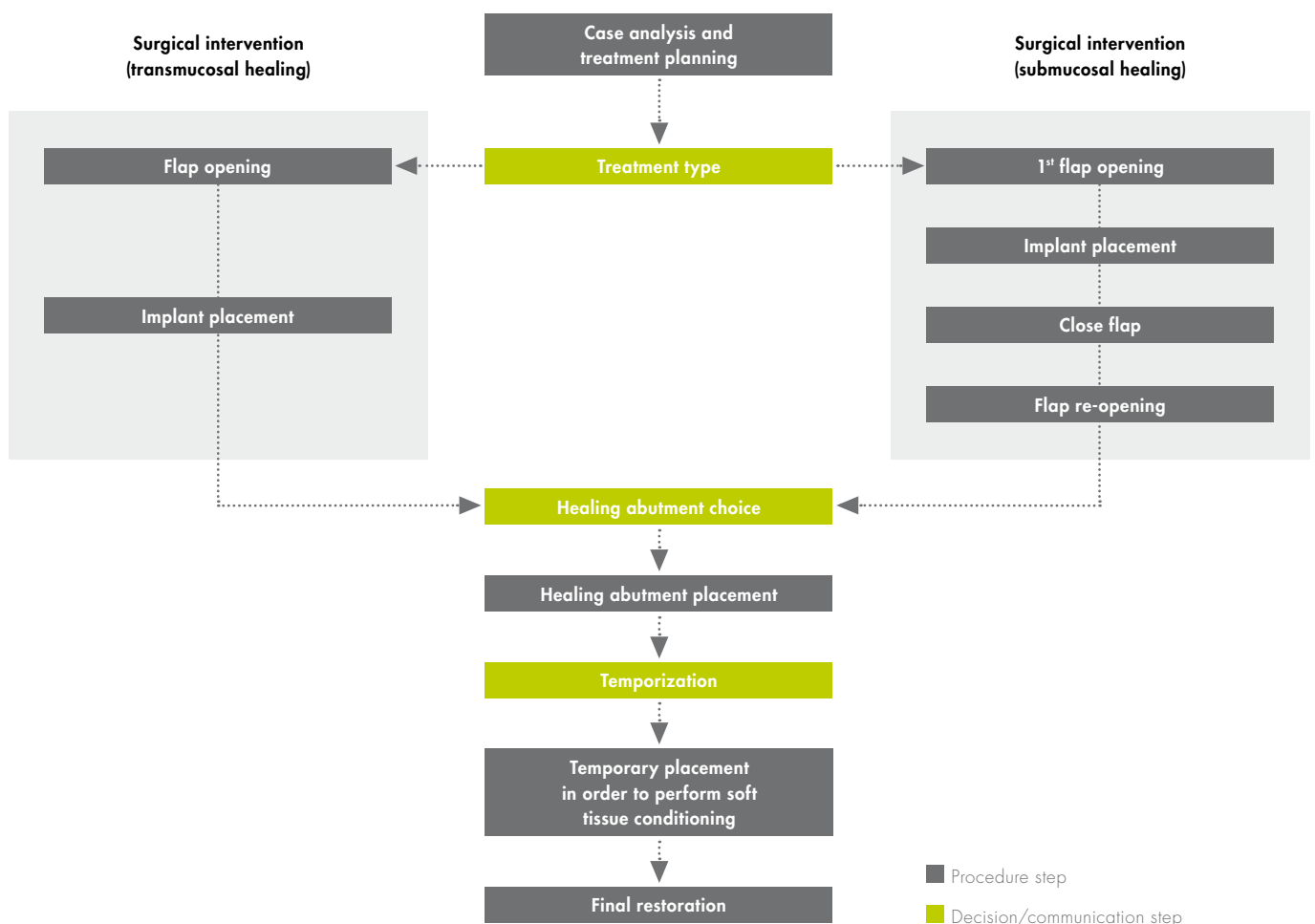COMMUNICATION IS KEY IN THE DENTAL IMPLANT TREATMENT FLOW

Interdisciplinary treatment planning includes the collaboration of different parties such as:

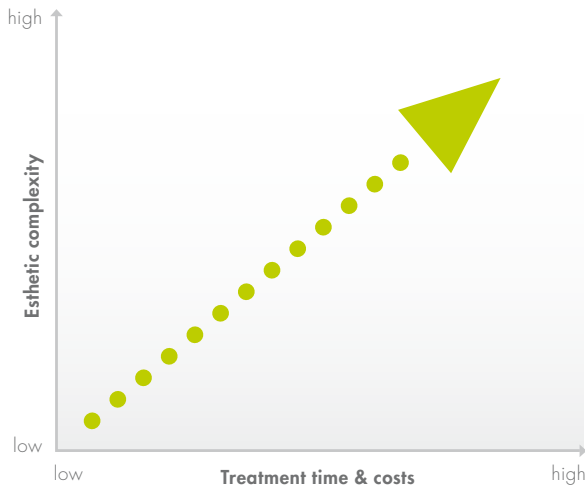- Patient
- General practitioner
- Surgeon
- Prosthodontist
- Dental laboratory

In order to reach a successful treatment outcome, communication between all involved is essential. The parties should be aware of the steps and interfaces and exchange their positions in order to be able to make the correct decisions.

A general overview of the treatment flow is depicted below, broken down into various treatment steps. Before each decision step (lime green in the picture below) communication can be helpful.



TREATMENT FLOW



I. Case analysis and treatment planning

Soft tissue management starts when planning the case because the soft tissue shape has to be analyzed and soft tissue conditioning is influenced by the implant placement. Each case is different; therefore accurate analysis and planning from the very beginning is helpful to reach the desired esthetic outcome. Various factors (e.g. indication, patient expectations, soft tissue shape, bone quality, site position) have an effect on the treatment outcome. The degree of complexity and risk involved in individual procedures can be assessed, for example, with the **ITI SAC Assessment Tool**¹. As a general principle the level of complexity rises with an increase in the number of steps involved and the esthetic outcome that must be achieved to attain a satisfactory result.

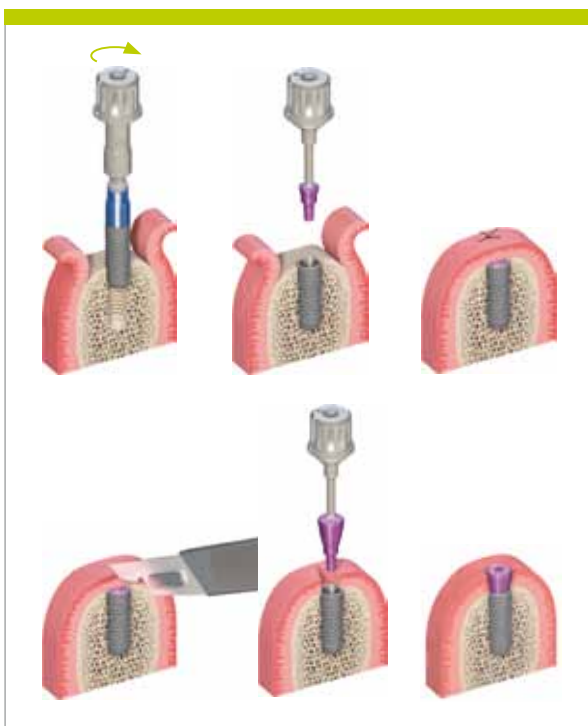
Increasing esthetic complexity leads in general to longer treatment time and higher costs. Informing and educating the patient at the beginning of the treatment might increase his or her willingness to collaborate.

II. Surgical treatment and healing phase

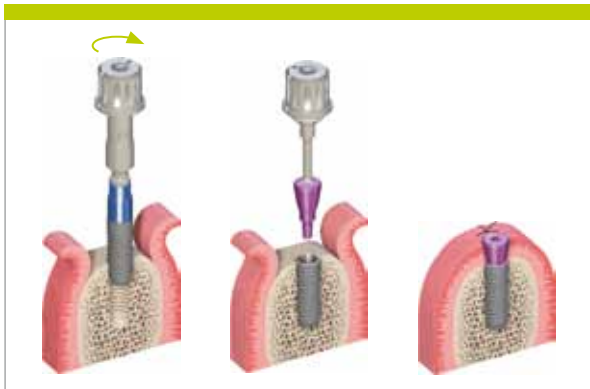
Based on the case and his or her preferences, the clinician will choose a submucosal or a transmucosal approach.

With the **submucosal approach**, a closure screw is placed after the implant placement and the flap is closed. In a second surgery after a first healing phase, the healing abutment is placed and soft tissue conditioning is started.

The healing abutment initiates the first phase of soft tissue contouring. Bone level healing abutments were designed in order to correlate with the size of the abutments for the final restoration. This concept is called '**Consistent Emergence Profiles**TM'.



Schematic depiction of the submucosal procedure, which requires two surgical interventions



Schematic depiction of the transmucosal procedure

The **transmucosal approach** allows a straightforward procedure, avoiding a second surgery.

The decision, as to which abutment to use for the final restoration needs to be made at beginning of the treatment so that the healing abutment can be chosen accordingly. Therefore, backward planning and good communication between the treating clinicians and the dental lab are needed. The tables on the following pages support the choice of the healing abutment by showing the best fit between conical healing abutment and the final restoration. There are further alternatives in the healing abutment portfolio (e.g. customizable abutments, bottle-shaped healing abutments) which are not displayed in the tables. These alternatives are meant to meet additional needs for individual cases and to be used based on user preferences. More details about these solutions can be found in the brochure "Basic information on the surgical procedures" (pages 60–65).

III. Temporization (shaping of the soft tissue)

After the first healing phase, the soft tissue can be shaped with the help of temporary abutments. This additional soft tissue conditioning with the temporary abutment may achieve an even more esthetic outcome and widen the soft tissue when needed (see cases on page 10–14). The papilla can be additionally shaped and adapted to the final restoration. For these steps, the patient has to be made aware about the additional effort which is needed to increase the esthetic outcome. Again, good communication with the dental lab and the treating clinicians supports the final outcome.

IV. Treatment closure and follow-up

Once the prosthesis is placed, adapted and the treatment is finished, regular follow-up visits and good oral hygiene help to prevent any undesired effects and to keep patient satisfaction high.

THE HEALING AND TEMPORARY ABUTMENT PORTFOLIO



Closure screws available for both platforms in 2 different heights.

In case of submucosal healing, closure screws are available in different heights for the different platforms (Narrow CrossFit® [NC] and Regular CrossFit® [RC]). These allow a simple submerged healing due to their reduced height and diameter (adapted to implant diameter).



Conical abutments are the straightforward solution for soft tissue management. They are available for both platforms in different diameters and heights.

In case of transmucosal healing or after re-opening in a submerged case, Straumann offers various **healing abutment** types. These abutments allow the soft tissue to be shaped.



In specific cases, e.g. thin mucosa type, a bottle shape abutment might be beneficial. Bottle-shaped abutments are available for both platforms in different heights.



For specific patient cases or if a cementable abutment with a diameter of 6.5 mm is used, the customizable abutment has shown to be the ideal solution. These abutments are available for both connection platforms.



PEEK temporary abutments are available for additive and subtractive procedures.

In general a **temporary restoration** is recommended to reach a good esthetic outcome. When a temporization is required two types of abutments are available: PEEK temporary and titanium temporary. These support additional soft tissue conditioning. One example is shown in the attached case.

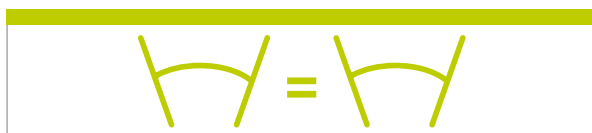
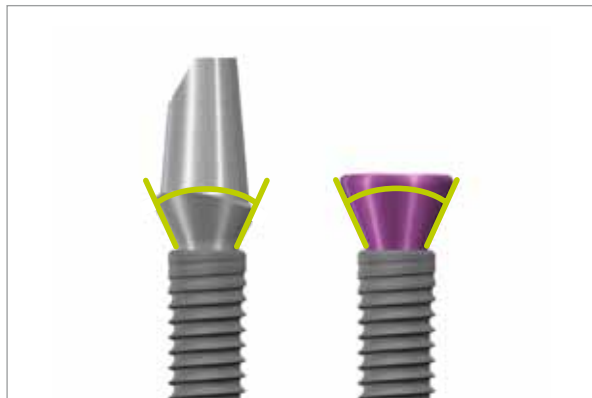The PEEK temporary abutment allows a subtractive and additive procedure to create a temporary restoration.



Titanium temporary abutments are available for additive procedures (3D view needed).

The titanium healing abutments are designed to build up a temporary restoration by adding material on the post.

THE CONSISTENT EMERGENCE PROFILES™ CONCEPT



The healing abutments, temporary abutments and final abutments of the Straumann® Bone Level implant system were designed to have an emergence profile which is the same at all treatment steps when combining specific products. For each final standard abutment (excluding Meso, Straumann® CARES® and gold abutments) there is a corresponding healing abutment. Accordingly, the final abutment will possess the same emergence profile that was previously created by the respective healing abutment. The pictures show examples of matching healing abutments and final abutments.

In the Straumann® portfolio there is a best fit combination between one final abutment and one conical healing abutment. The examples are depicted showing a final abutment with the specific conical healing abutment which fits the best. Tables on the following pages can be consulted in order to find the healing abutment which is the best fit for a specific final abutment. Key properties of the final abutment are type (e.g. Multi-base abutment), abutment diameter (Ø) and gingival height (GH). Abutment height (AH), angle and material do not affect the choice of the healing abutment. Once these parameters are known a corresponding healing abutment can be chosen.

The tables on page 7–9 include only the best fit between the conical healing abutment and the final abutment. Detailed information about the possible combinations of all Straumann® healing abutments with the final abutments can be found in the brochure “Basic information on the surgical procedures” (pages 60–65).

CEMENT-RETAINED SOLUTIONS

Platform	NC														
Type	Anatomic abutment						Cementable abutment								
	Material	Ti		Ti		IPS e.max®		IPS e.max®		Ti			Ti		
Angle	0°		15°		0°		15°		0°			0°			
Ø (mm)	4.0		4.0		4.0		4.0		3.5			5.0			
GH (mm)	2.0	3.5	2.0	3.5	2.0	3.5	2.0	3.5	1.0	2.0	3.0	1.0	2.0	3.0	
	⋮	⋮	⋮	⋮	⋮	⋮	⋮	⋮	⋮	⋮	⋮	⋮	⋮	⋮	
GH (mm)	3.5	5.0	3.5	5.0	3.5	5.0	3.5	5.0	3.5	3.5	5.0	3.5	5.0	5.0	
Ø (mm)	4.8				4.8				4.8		3.6		4.8		
Type															
	Conical healing abutment														

Platform	RC														
Type	Anatomic abutment						Cementable abutment								
	Material	Ti		Ti		IPS e.max®		IPS e.max®		Ti			Ti		
Angle	0°		15°		0°		15°		0°			0°			
Ø (mm)	6.5		6.5		6.5		6.5		5.0			6.5			
GH (mm)	2	3.5	2	3.5	2	3.5	2	3.5	1.0	2.0	3.0	1.0	2.0	3.0	
	⋮	⋮	⋮	⋮	⋮	⋮	⋮	⋮	⋮	⋮	⋮	⋮	⋮	⋮	
GH (mm)	4.0	6.0	4.0	6.0	4.0	6.0	4.0	6.0	2.0	4.0	6.0	2.0	4.0	6.0	
Ø (mm)	6.0				6.0				6.0		6.0		6.0		
Type															
	Conical healing abutment														

SCREW-RETAINED SOLUTIONS

Platform	NC											
Type	Anatomic abutment				Multi-base abutment							
Material	IPS e.max®		IPS e.max®		Ti			Ti			Ti	
Angle	0°		15°		0°			0°			15°	
Ø (mm)	4.0		4.0		3.5			4.5			4.0	
GH (mm)	2.0	3.5	2.0	3.5	1.0	2.5	4.0	1.0	2.5	4.0	2.5	
	⋮	⋮	⋮	⋮	⋮	⋮	⋮	⋮	⋮	⋮	⋮	⋮
GH (mm)	3.5	5.0	3.5	5.0	2.0	3.5	5.0	2.0	3.5	5.0	3.5	
Ø (mm)	4.8				3.6			4.8			4.8	
Type												
	Conical healing abutment											

Platform	RC											
Type	Anatomic abutment				Multi-base abutment							
Material	IPS e.max®		IPS e.max®		Ti			Ti			Ti	
Angle	0°		15°		0°			0°			15°	
Ø (mm)	6.5		6.5		4.5			6.5			4.0	
GH (mm)	2	3.5	2	3.5	1.0	2.5	4.0	1.0	2.5	4.0	2.5	
	⋮	⋮	⋮	⋮	⋮	⋮	⋮	⋮	⋮	⋮	⋮	⋮
GH (mm)	4.0	6.0	4.0	6.0	2.0	4.0	6.0	2.0	4.0	6.0	4.0	
Ø (mm)	6.0				4.5			6.0			6.0	
Type												
	Conical healing abutment											

SCREW-RETAINED SOLUTIONS

Platform	NC											
Type	Multi-base abutment						LOCATOR®					
Material	Ti			Ti			Ti			Ti alloy		
Angle	0°			0°			15°			0°		
Ø (mm)	3.5			4.5			4.0			3.8		
GH (mm)	1.0	2.5	4.0	2.0	2.0	3.5	2.5	2.0	3.0	4.0	5.0	6.0
	↓			↓			↓			↓		
GH (mm)	2.0	3.5	5.0	2.0	3.5	5.0	3.5	2.0	3.5	5.0		
Ø (mm)	3.6			4.8			4.8			3.6		
Type	Conical healing abutment			Conical healing abutment			Conical healing abutment			Conical healing abutment		

Platform	RC												
Type	Multi-base abutment						LOCATOR®						
Material	Ti			Ti			Ti			Ti alloy			
Angle	0°			0°			15°			0°			
Ø (mm)	4.5			6.5			4.0			3.8			
GH (mm)	1.0	2.5	4.0	1.0	2.5	4.0	2.5	1.0	2.0	3.0	4.0	5.0	6.0
	↓			↓			↓			↓			
GH (mm)	2.0	4.0	6.0	2.0	4.0	6.0	4.0	2.0	4.0	6.0			
Ø (mm)	4.5			6.0			6.0			4.5			
Type	Conical healing abutment			Conical healing abutment			Conical healing abutment			Conical healing abutment			

CASE EXAMPLE FOR SOFT TISSUE CONDITIONING

Every patient is an individual case and may need to be treated in a different way. Accordingly, the following case shows one treatment strategy and procedure and illustrates how soft tissue conditioning can be handled to reach an esthetic result. The process in the cases corresponds to the previously explained treatment flow (page 1–2) and is always the result of the collaboration of different parties.

Case: Soft tissue conditioning with the dynamic compression technique²

(Courtesy of Dr. Wittneben)

The following treatment was performed at the University of Berne in Switzerland. Various parties were involved in this patient's case. The surgery was performed by Prof. Dr. D. Buser, soft tissue conditioning and the prosthodontic treatment was accomplished by Dr. J. Wittneben and the dental laboratory work was done by CDT T. Fuhrter from ArtDent in Berne. Extensive communication and continuous information exchange between the treating parties were essential for the treatment. The patient was also involved and well-educated during the treatment.

Case analysis and treatment planning

A 21-year-old, non-smoking female patient was referred to the Oral Surgery Department from a private practice because tooth 11 presented an acute fistula including an external root resorption following trauma. The patient was referred from the Oral Surgery Department to the Department of Fixed Prosthodontics, University of Berne, to perform a combined surgical-prosthodontic treatment approach.

At the initial examination, the patient's chief complaint was bad odor and pus emerging from the fistula – she wanted to have a final treatment of her anterior tooth. The extraoral examination showed no pathological findings. The intraoral examination revealed that her teeth were all natural and non-restored except for tooth 11, which presented with a composite restoration with discoloration and wear. In the radiographic analysis the diagnosis of a well-defined lateral root resorption could be confirmed presenting in the CT as well as in the periapical radiograph.



Prof. Dr. D. Buser, Dr. J. Wittneben, CDT T. Fuhrter (f.l.t.r.)

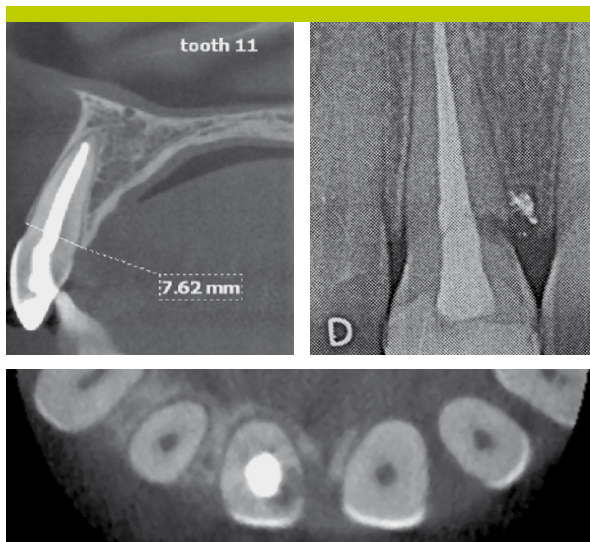


Figure 1: Initial situation presenting external root resorption in position 11; thin buccal plate is visible in cone beam CT diagnostic

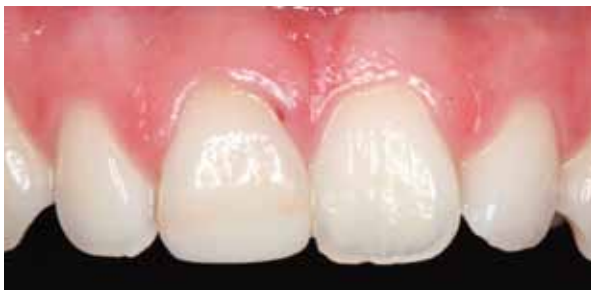
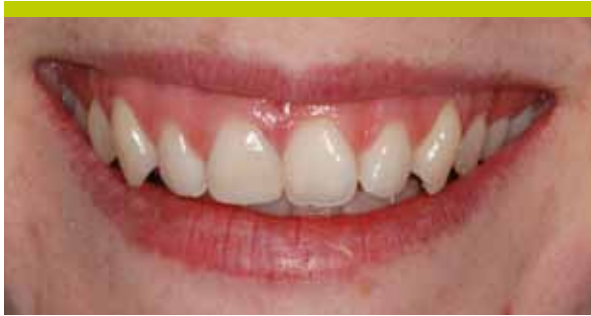
Figure 2: The young patient has a high lip line, thin gingiva biotype, a highly scalloped gingiva and triangular-shaped anterior teeth

Therefore, tooth 11 was considered hopeless and implant therapy was recommended as the neighboring teeth were non-restored.

Due to her young age and no previous experiences with dental treatments other than in area 11, the patient had high esthetic expectations. At full smile, the patient presented a high lip line, exposing all anterior maxillary teeth and surrounding gingiva.

The gingival biotype was thin and highly scalloped with triangular-shaped anterior teeth. These findings led to the following SAC profile¹: complex, because of the esthetic risk factors involved.

The oral surgeon and prosthodontist discussed the case with and without the patient. It was important to evaluate the patient's expectation before starting the treatment. The patient was also informed about the length of the treatment and its implications. She agreed and was willing to collaborate.

The dental technician was also introduced to the patient and the final position of the implant was discussed with all clinicians on the basis of a wax-up. During the planning phase, the decision was made to resolve this case with a screw-retained ceramic abutment. This decision was based on the anatomical situation (frontal tooth, high lip line) and the patient's expectations regarding the esthetic outcome.

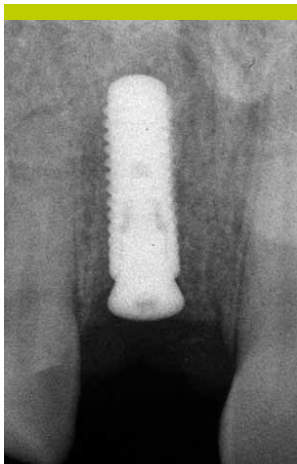


Figure 3: X-ray showing ideal implant placement and the first conical healing abutment (RC Ø 4.5 mm) placed for the healing phase 1

Surgical treatment and healing phase

The tooth extraction was performed carefully without the elevation of a flap in the Oral Surgery Department by Prof. Dr. Buser. Exactly 6 weeks later (early placement concept) a Straumann® Bone Level SLActive Implant with a diameter of 4.1 mm (RC platform) was inserted by the same clinician, including Guided Bone Regeneration (GBR). The implant was placed in a correct three-dimensional position and, when primary stability was achieved, GBR technique was added. The flap was closed for submucosal healing due to simultaneous GBR procedure.

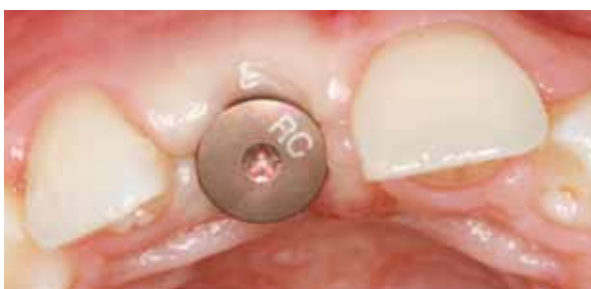
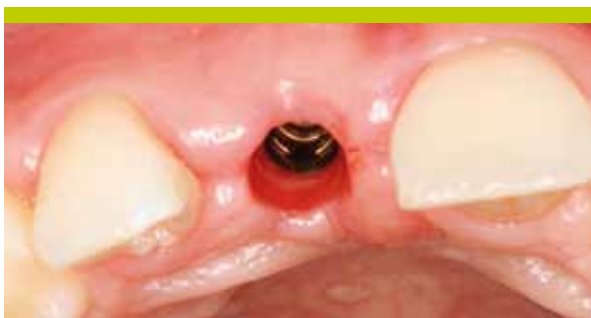
Figure 4: The narrow healing abutment has been replaced by a wider healing abutment to widen the soft tissue

The patient received a simple flipper as an interim provisional denture during the time of healing. After 10 days the denture tooth had to be modified by adding material. After the reopening procedure, a conical healing abutment (Ø 4.5 mm) for the RC platform was inserted. Soft tissue conditioning starts with the first insertion of the healing abutment. After taking the impression for the provisional, a larger diameter (6 mm) was chosen to prepare the site for insertion of the temporary abutment with the provisional.

To improve the mucosa architecture surrounding the future implant crown, soft tissue conditioning with the “dynamic compression technique” was performed.

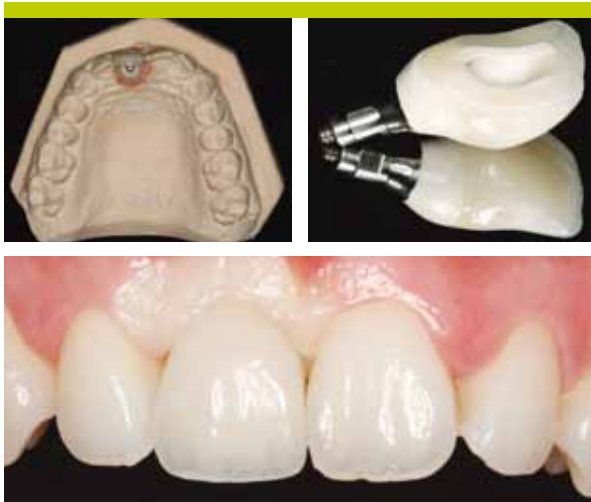

Figure 5: A slightly overcontoured provisional crown has been placed. An ischemic reaction can be observed, which disappeared 10 to 15 minutes after crown placement

Soft tissue conditioning with the “dynamic compression technique”

Using the early loading concept, a screw-retained implant-supported provisional (PEEK Temporary abutment) was inserted after 6 weeks post placement. The shape of the provisional crown was slightly overcontoured in order to create pressure, to form the mucosa, the emergence profile and to have an approximal contact present. As a temporarily effect, there was an ischemic reaction (white soft tissue) for about 10 to 15 minutes, after this time, the soft tissue returned to its pink color.

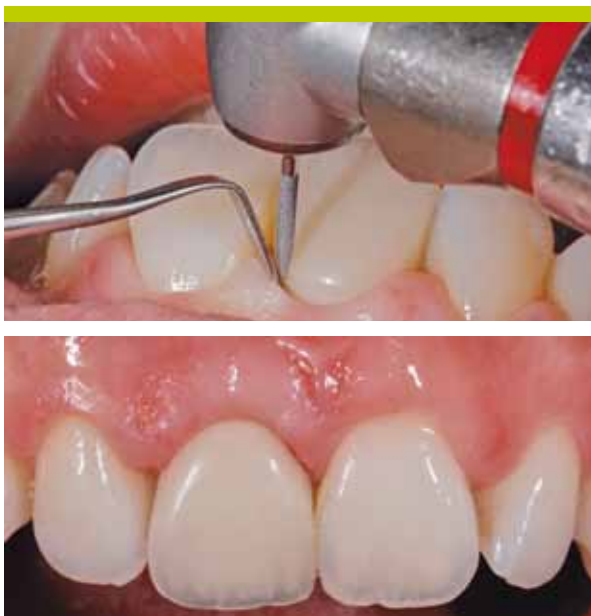

Figure 6: After two weeks of pressure phase the release phase is initiated by removing acrylic material intraorally

During the following 2 weeks, selective pressure was applied (pressure phase) to the provisional crown by adding extraorally light-cured acrylic material. After 2 weeks, the shape of the provisional was modified by removing acrylic material in the interproximal/cervical area in order to create space for the papillae (release phase). This approach is performed in several steps and can be done intraorally with a fine diamond bur and then polished with an arkansas stone – without removing the provisional.

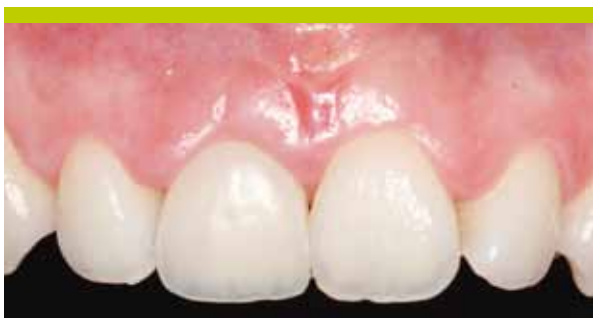

Figure 7: Period after provisional crown placement: 20 days

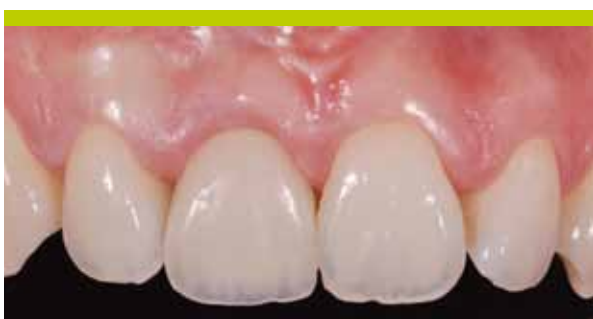

Figure 8: Period after provisional crown placement: 2.5 months

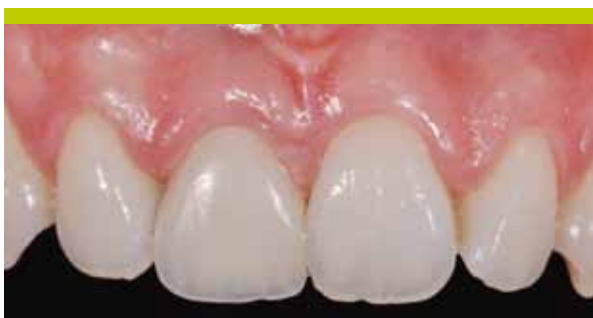

Figure 9: Period after provisional crown placement: 5 months; finalized soft tissue architecture and end of provisional phase

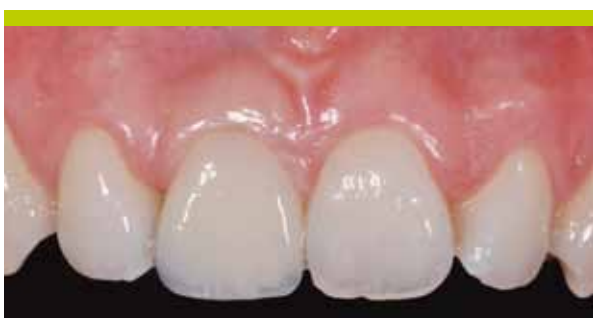

Figure 10: Final restoration

Soft tissue conditioning is recommended for 3–5 months for single edentulous gaps and for 6–8 months for adjacent implants in the esthetic zone. In the present case, soft tissue conditioning was performed for 5 months. The patient is visiting the prosthodontist at a regular basis for the removal of material.

The created final soft tissue architecture and emergence profile were transferred to the final master cast by the fabrication of an individualized impression coping.

Treatment closure and follow-up

For the final reconstructive design, a screw-retained single implant crown was chosen and an individualized zirconium dioxide Straumann® CARES® customized abutment was fabricated.

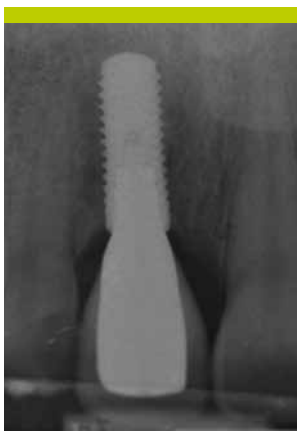


Figure 11: Radiograph of the final restoration

The planned abutment was waxed up and scanned via the Straumann® CARES® Visual software and a zirconium dioxide abutment was delivered. Feldspathic ceramic was hand-layered on top of the abutment. The final restoration was inserted with 35 Ncm. The occlusion was adjusted.

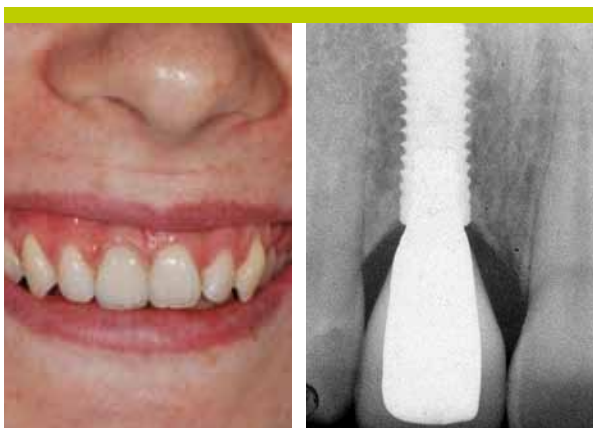

Figure 12: One year after treatment start, a follow-up visit revealed stable soft tissue and crestal bone

The follow-up after 1 year showed no changes in soft tissue architecture or in implant crown. This was also confirmed by a prospective clinical study on Bone Level implants with early placement, contour augmentation and early loading concept in single edentulous space in the esthetic zone – there were no changes in the overall esthetics (pink and white esthetic parameters) over a follow-up time of 3 years.²

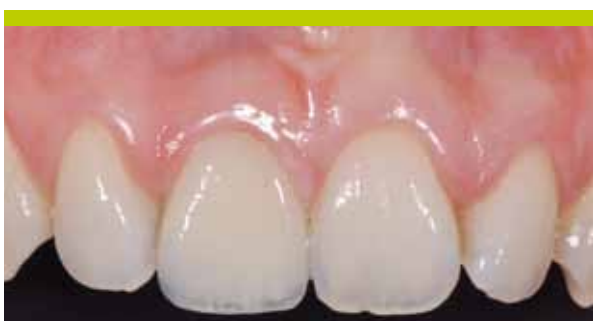

Figure 13: One year after treatment start

We are thankful to Dr. Julia-Gabriela Wittneben (University of Berne) for providing this case and all accompanying figures.

REFERENCES

- ¹ Dawson A, Chen S, Buser D, Cordaro L, Martin W, Belser U. *The SAC Classification in Implant Dentistry: Straightforward – Advanced – Complex.* In Dawson A. and Chen S (eds):2009:Quintessence Publishing Group.
- ² Buser D, Wittneben J, Bornstein MM, Grütter L, Chappuis V, Belser UC. *Stability of contour augmentation and esthetic outcomes of implant-supported single crowns in the esthetic zone: 3-year results of a prospective study with early implant placement postextraction.* J. Periodontol. 2011;82(3):342–9.

www.straumann.com



STRAUMANN GUARANTEE

International Headquarters

Institut Straumann AG
Peter Merian-Weg 12
CH-4002 Basel, Switzerland
Phone +41 (0)61 965 11 11
Fax +41 (0)61 965 11 01

IPS e.max® is a registered trademark of Ivoclar Vivadent AG, Liechtenstein.
LOCATOR® is a registered trademark of Zest Anchors, Inc., USA.

© Institut Straumann AG, 2011. All rights reserved.

Straumann® and/or other trademarks and logos from Straumann® mentioned herein are the trademarks or registered trademarks of Straumann Holding AG and/or its affiliates. All rights reserved.